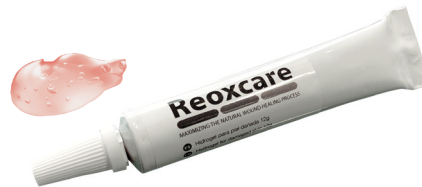
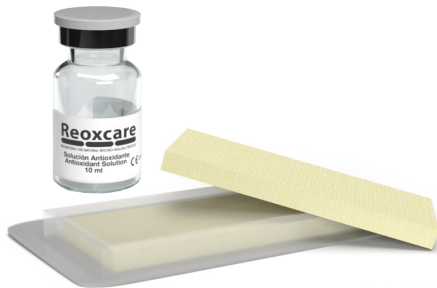
Reoxcare

MAXIMIZING THE NATURAL WOUND HEALING PROCESS

SKIN AND WOUND CARE PRODUCTS

A new approach to wound care



What is Reoxcare Line

Reoxcare is an innovative line of skin and wound care products with antioxidant properties.

Reoxcare products promote the skin's natural repair process.

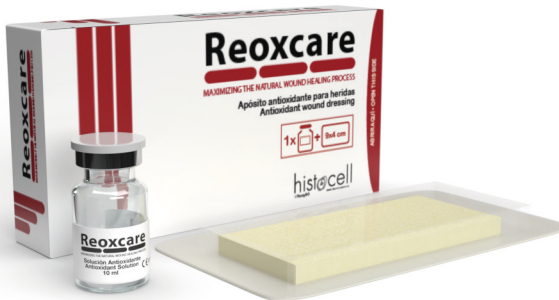All Reoxcare products are formulated with ingredients of natural origin.

Reoxcare Sterile Dressing

Reoxcare is an innovative next-generation dressing with unique antioxidant properties, which reactivates the healing of complex wounds.

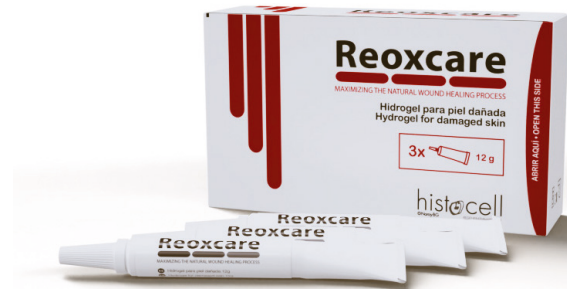Reoxcare Gel

Reoxcare Gel is a new hydrogel with antioxidant ingredients for the prevention and treatment of skin lesions.



Presentation

Each box contains a 9x4 cm matrix and a 10 ml vial.




Presentation

Each box contains three 12g tubes.

Antioxidant ingredients of natural origin



LBG (galactomannan)
Obtained by grinding the seeds of the carob tree. A reference in traditional medicine for its antioxidant and very soothing properties.



Turmeric
Source of vitamins and minerals. Prevents tissue oxidation and provides a defence against the inflammatory environment.

Reoxcare Dressing



Acetylcysteine
Amino acid common in a variety of foods. Powerful antioxidant action. Biofilm control.



Lycopene*
Natural carotene, direct neutraliser of the most abundant free radicals present in oxidative stress. Blocker of the oxidative cascade.



Ascorbic acid*
Essential micronutrient for wound healing. Necessary for the synthesis and stabilisation of collagen, providing strength and resistance to newly formed tissue.

Reoxcare Gel

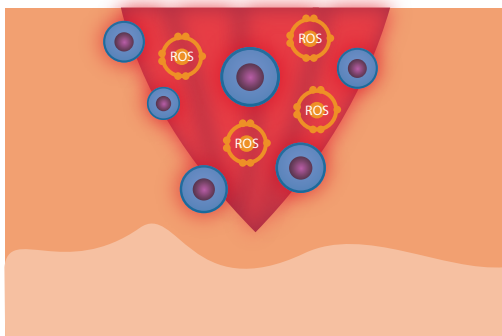


α -Tocopherol*
Recognised natural antioxidant. Reduces the formation of free radicals and protects cell membranes.


*Excipients

The science behind the product

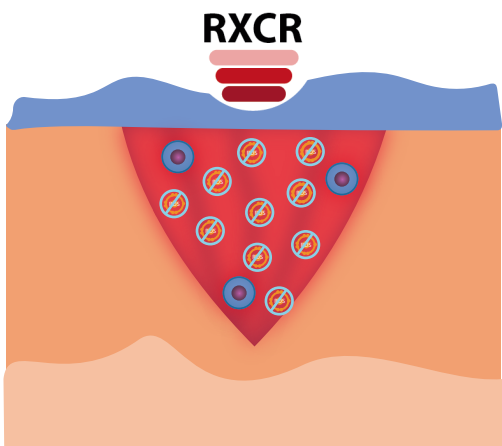
Antioxidant action




Inflammatory cells produce free radicals.



When there is an excess of free radicals, healing stops.



Reoxcare neutralises excess free radicals by maintaining a moist environment.



And it allows the tissues to progress towards healing.

Properties of Reoxcare products

Antioxidant

Neutralises excess free radicals in the environment, contributes to the healing process.

Debridement

Facilitates the removal of non-viable tissue present in the wound bed.

Pain relief*

The moisturising and antioxidant properties work in combination to reduce pain in and around the wound.

Wound Healing

Use

Easy to apply and remove.

*See scientific publications and references

Wound activation

Preparation of the bed, granulation tissue induction and edge activation.

Biofilm

Prevents biofilm from interfering with wound healing.

Reoxcare Dressing

Skin protective and repairing

Protects healthy skin from continuous exposure to moisture and repairs damaged skin after aggressions.

It can be applied by the patient.

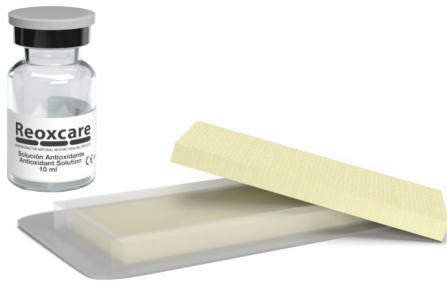Reoxcare Gel

Reoxcare Dressing

What is Reoxcare Dressing?

Reoxcare Dressing is an innovative, state-of-the-art treatment with unique antioxidant properties, which promotes the natural wound healing process.

Its novel and patented design is the result of HistoCell's years of research in regenerative medicine.



Indications

Reoxcare can be used on ulcers and wounds of different aetiology:

- Diabetic foot ulcers
- Pressure ulcers
- Hypertensive ulcers
- Venous ulcers with compression treatment
- Ulcers with ischaemic component
- Calciphylaxis ulcers
- Surgical dehiscences
- Burns
- Traumatic wounds

How does Reoxcare Dressing work?

Reoxcare combines 2 components of natural origin for optimal skin care.

100% plant-based matrix with high absorption capacity



Hydration solution with antioxidant properties



Advantages

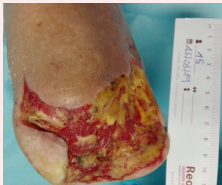Reoxcare is an effective treatment for both acute and chronic wounds. It prevents the chronification of wounds. It activates the wound, obtaining an optimal wound bed that allows the natural healing process. It has an excellent debridement capacity, both osmotic and autolytic. Prevents the interaction of biofilm in the healing process.

Clinical cases

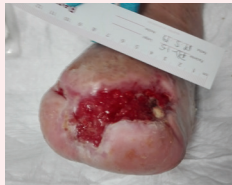

Diabetic foot ulcer

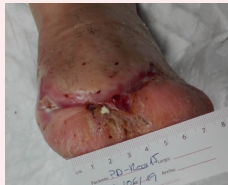58-year-old male patient with type II diabetes. Surgical wound after transmetatarsal amputation.



Beginning



Week 8



Week 13

1 month in evolution

Previous treatment

Negative pressure therapy for one month after surgery.

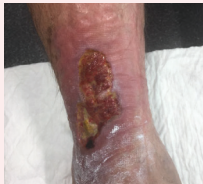Treatment with Reoxcare Dressing

Application of Reoxcare Dressing in the wound bed + hydrocolloid hydrofiber with silicone dressing.

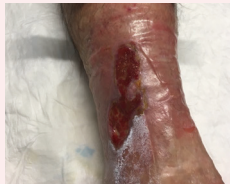

Venous ulcer

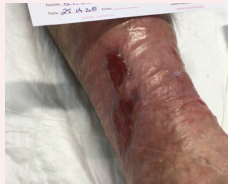62-year-old male patient with a history of venous insufficiency.



Beginning



Week 3



Week 6

5 months in evolution

Previous treatment

Various CAH treatments, oral antibiotherapy for positive cultures and compressive therapy.

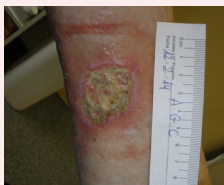Treatment with Reoxcare Dressing

Application of Reoxcare Dressing to the wound bed, non-adhesive foam dressing and compressive therapy. Cures every 4 days. After one month, due to significant healing progress, the dressing is changed to foam dressing and compression therapy until closure.

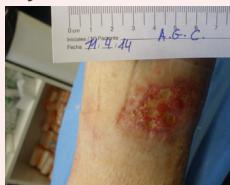

Hypertensive wound

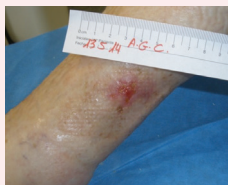84-year-old woman with type II diabetes, insulin-dependent, hypertension and venous insufficiency.



Beginning



Week 8



Week 13

18 months in evolution

Previous treatment

Multiple products. The patient does not tolerate the bandage because she refers to pain.

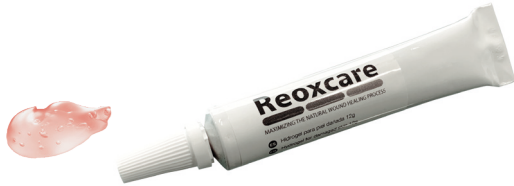Treatment with Reoxcare Dressing

Application of Reoxcare Dressing to the wound bed and foam dressing as a secondary dressing. Cures every 48-72 hours for high level of exudate.

Reoxcare Gel

What is Reoxcare Gel?

Active hydrogel that provides a defence against free radicals present in the environment of damaged skin and wounds.



What does Reoxcare Gel provide?

High antioxidant capacity

Hydrates the skin

Filmogenic effect

Provides essential trace elements for cellular mechanisms

Excellent clinical results *



Reduces inflammation, irritation and pain



Autolytic debridement capability

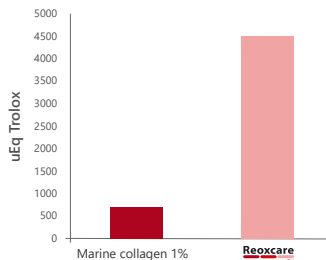


Protects both intact and damaged skin

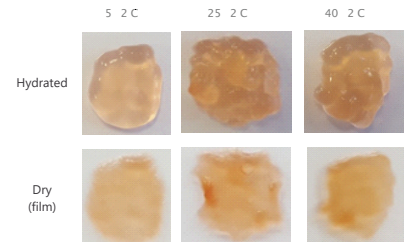


Increased tissue repair and healing capacity

*See scientific publications and references



Reoxcare Gel has a high capacity for direct free radical scavenging, providing a high antioxidant defence.



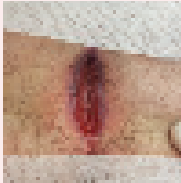Reoxcare Gel generates a tough film that protects the skin against the external environment.

Clinical cases

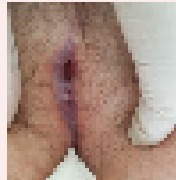

Pilonidal sinus


Patient aged 22 years. Asthma. Bronchospasm. Allergy. Reintervention of pilonidal sinus.



Beginning



Week 6



Week 7

3 months in evolution

Previous treatment

Multiple ineffective treatments. Chlorhexidine + diacylcarbanyl chloride dressing + support dressing.

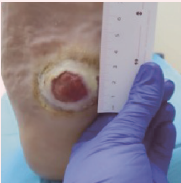
Treatment with Reoxcare Gel

Sharp debridement + Reoxcare Gel + antimicrobial dressing with silver + foam dressing.

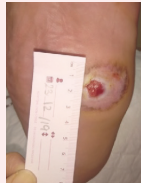

Neuropathic ulcer in Charcot's foot

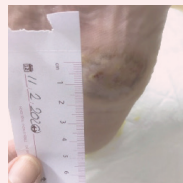
Patient aged 51 years. Diabetes mellitus.



Beginning



Week 3



Week 11

6 months in evolution

Previous treatment

Daily cures with moist wound healing dressing for high serous exudate.

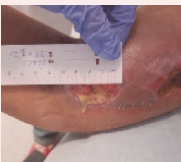Treatment with Reoxcare Gel

Cleaning + Reoxcare Gel + polyvinyl alcohol hydrophobic + adhesive foam + discharge.

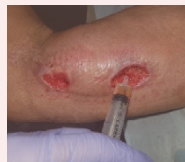

Surgical wound

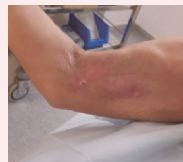Patient aged 53 years. Renal transplant. Peritoneal dialysis. Operated on humero-basilic arteriovenous fistula.



Beginning



Week 2



Week 6

1 month in evolution

Previous treatment

Treatment with antimicrobial cream with silver. Subsequent debridement dressing + hydrofibre + bandage.

Treatment with Reoxcare Gel

Sharp debridement + Reoxcare Gel + polyurethane foam until wound closure.

How to use Reoxcare Dressing

How is Reoxcare Dressing used?






- Hydrate the matrix with the solution and wait 1-2 minutes.
- Clean the wound.
- Protect the perilesional skin with barrier film, at the discretion of the practitioner.
- Trim the matrix to fit the shape of the bed and lay it in the bed.
- Use an appropriate moist wound dressing.
- Change twice weekly (every 3-4 days).

Reoxcare Dressing is a single use product. Do not use if the package is open or damaged. Do not use in case of known hypersensitivity to any of its components.

Which secondary dressing should be used with Reoxcare?

Reoxcare is compatible with commonly used secondary dressings.

The most appropriate dressing should be selected according to the level of wound exudation.

Exudate level	Secondary dressing
	Alginate Polyvinyl fibre Hydrocolloid hydro fibre Superabsorbent hydroactive dressing  <i>In heavily exuding wounds use a second secondary dressing of foam type with adhesive silicone.</i>
	Polyurethane foam with adhesive silicone Hydrocolloid hydro fibre with silicone
	Polyurethane film  <i>In very slightly exuding wounds, to maintain moisture and prevent drying out, Reoxcare can be covered with amorphous or conformable hydrogel.</i>

How is Reoxcare Gel used?

1

Gently clean the area.

2

Apply Reoxcare Gel over the area each 24/48 hours until complete healing.

3

Cover if necessary.



Reoxcare Gel can be used by the patient.

Reoxcare Gel is a single use product. Do not use if the container is open or damaged. Do not use in case of known hypersensitivity to any of its components or to tomato derivatives.

Reoxcare Dressing or Reoxcare Gel

Reoxcare
Gel



Reoxcare
Dressing



Level of complexity of wounds

Prevention and treatment of moisture-related injuries

Irritations/abrasions

Burns

GI

GII

GIII

GIV

DFU

TX 0-A/C

TX I-A/C

TX II-C

TX III-C

PU

CI

CII

CIII

CIV

Acute wounds

Complex wounds

Surgical dehiscence

Prevention and treatment

Scientific publications and references

- Pérez-Zabala E, Basterretxea A, Castro B, Aizpuru A, Arancón JA, Moreno C, Zubizarreta A, Larizgoitia Z, Ysa A, Lobato M, Larrazabal A. New antioxidant therapy for hard-to-heal neuroischaemic diabetic foot ulcers with deep exposure. *Journal of Wound Care* vol 32, No 4, April 2023.
- Arboledas J, Encinas L, Lozano E. Aplicación de una terapia antioxidante en el tratamiento de quemaduras en pacientes pediátricos. Póster presentado en el XIII Simposio Nacional sobre Úlceras por Presión y Heridas Crónicas (GNEAUUPP), Toledo, España (noviembre 2021).
- Blanco I, Arancón JA, Pérez ME, Pomposo L, Bermejo C, Agirre Ainize, Esteban C. Aplicación de apósito antioxidante en dehiscencia externa como alternativa a terapia de presión negativa tópica. Póster presentado en el XIII Simposio Nacional sobre Úlceras por Presión y Heridas Crónicas (GNEAUUPP), Toledo, España (noviembre 2021).
- Blanco I, Arancón JA, Pérez ME, Larrazabal A, Pomposo L, Ruiz de Gauna A, Lobato L. Cuando el abordaje multidisciplinar es clave para mantener la funcionalidad ante una amputación por isquemia de grado IV. Póster presentado en el XIII Simposio Nacional sobre Úlceras por Presión y Heridas Crónicas (GNEAUUPP), Toledo, España (noviembre 2021).
- Comino Sanz IM, López-Franco MD, Castro B, Pancorbo-Hidalgo PL. The role of antioxidants on wound healing: a review of the current evidence. *Journal of Clinical Medicine*. 2021, 10, 3558.
- Jiménez-García JF, Aguilera-Manrique G, Parra-Anguita L, Torra-Bou JE, Villegas-Tripiana I, García-Fernández FP. An antioxidant approach directed to non-healing wounds activation – A case report study. *Clinical Cases Reports and Reviews*. 2021 Volume 7:1-6
- Jiménez García JF, Abad García MM, Ortiz Villegas L, Zarco Marín JM, Expósito Torres R, García Fernández FP. Cicatrización de úlceras venosas complejas mediante el control del estrés oxidativo. *Rev ROL Enferm* 2018; 41(11-12).
- Castro B, Bastida FD, Segovia T, López Casanova P, Soldevilla JJ, Verdú-Soriano J. The use of an antioxidant dressing on hard-to-heal wounds: a multicentre, prospective case series. *J Wound Care*. 2017;26:742-50.
- Castro B, Palomares T, Azcoitia I, Bastida F, Del Olmo M, Soldevilla JJ, et al. Development and preclinical evaluation of a new galactomannan-based dressing with antioxidant properties for wound healing. *Histol Histopathol*. 2015;30:1499-512.
- Tessari M, Tessari L. Un nuevo apósito antioxidante para heridas para el tratamiento de úlceras crónicas en pierna. Póster presentado en el 29º Congreso de la EWMA, Gotemburgo, Suecia (junio 2019).
- Jiménez García JF, Castro Feo B, Abad García MM, Porras Pastor JM, García Fernández FP. Control del estrés oxidativo para la activación de heridas: serie de casos. Póster presentado en el 29º Congreso de la EWMA, Gotemburgo, Suecia (junio 2019).
- Basterretxea Ozamiz A, Castro Feo B, Larrazabal Arbaiza A, Pérez Zabala E, Aizpuru Martínez A, Pérez del Pecho C, Iglesias Sainz-Maza E, Arancón Vaquero JA. El manejo adecuado del estrés oxidativo en el entorno de la herida mejora significativamente la curación de las úlceras neuroisquémicas del pie diabético postquirúrgico. Póster presentado en el 8º International Symposium on the Diabetic Foot, La Haya, Países Bajos (mayo 2019).
- Fondo E, Gómez R, de Agreda A, Santiso E, Rodríguez V, Cerame S. Efecto del control del estrés oxidativo en úlceras de Martorell. Comunicación oral presentada en el 8º Congreso SEHER, Madrid, España (febrero 2019).
- Pérez del Pecho C, Larrazabal A, Pérez E, Aizpuru A, Basterretxea A, Iglesias E. Cicatrización de úlceras de pie diabético post-operatorias de componente neuroisquémico mediante el control del estrés oxidativo: serie de casos. Póster presentado en la X Reunión Nacional Sección de Pie Diabético de la SEACV, Donostia-San Sebastián, España (diciembre 2018).
- Agreda A, Fondo E, Castrillón C, Santiso E, Rodríguez V, Gómez R, Cerame S. Aplicación de un apósito antioxidante en la cicatrización de heridas complejas de etiología vascular. Póster presentado en el XII Simposio Nacional sobre Úlceras por Presión y Heridas Crónicas (GNEAUUPP), Valencia, España (noviembre 2018).
- Jiménez García JF, Castro Feo B, Abad García MM, Porras Pastor JM, Ardit Lucas RA, García Fernández FP. Evaluación económica en la medición de la efectividad de un apósito bioactivo antioxidante en heridas crónicas. Póster presentado en el XII Simposio Nacional sobre Úlceras por Presión y Heridas Crónicas (GNEAUUPP), Valencia, España (noviembre 2018).
- Fondo E, Castrillón C, Santiso E, Gutiérrez N, Lopezosa A, de Agreda A, Harkot O, Novo E, Cerame S. Aplicación de un nuevo tratamiento antioxidante en la curación de heridas venosas tórpidas. Póster presentado en el XXX Congreso Nacional de Enfermería Vascular y Heridas, Madrid, España (junio 2018).
- Jiménez García JF, Porras Pastor JM, Zarco Marín JM, García Romera EM, Sánchez Escandell MA, Castro Feo B. Novel antioxidant treatment that improves the healing of chronic wounds. Póster presentado en el 28º Congreso de la EWMA, Cracovia, Polonia (mayo 2018).
- Fondo Álvarez E, Santiso Casanova E, Harkot O, Castrillón Díaz C, Gutiérrez Bandera N, García Jurado R, Cerame Perez S. Efecto de un apósito antioxidante sobre la activación de heridas crónicas. Póster presentado en el 7º Congreso SEHER, Madrid, España (febrero 2018).
- Arizmendi Pérez M, Sánchez de Luna Rodríguez M. Efecto del nuevo apósito antioxidante Reoxcare® en la cicatrización de úlceras vasculares. Póster presentado en el XXIX Congreso Nacional de Enfermería Vascular y Heridas, Gijón, España (junio 2017).
- Arizmendi Pérez M., Sánchez de Luna Rodríguez M, López García E, Moreno Martín M. Efecto de un apósito antioxidante en la cicatrización de úlceras isquémicas. Póster presentado en el 6º Congreso SEHER, Madrid, España (febrero 2017).
- Ensayo Clínico EC-HR006.01. Evaluación prospectiva del nuevo apósito HR006 para la cicatrización de las heridas crónicas.
- Ensayo Clínico EC-REOX CARE.UPD. Prueba de concepto: estudio prospectivo del nuevo apósito Reoxcare para mejorar la cicatrización en úlceras de pie de diabético.
- Ensayo Clínico EC-REOX CARE.UPP. Prueba de concepto: estudio prospectivo del nuevo apósito Reoxcare para mejorar la cicatrización en úlceras por presión.
- Instrucciones de uso SC01403291119. Fecha de revisión: noviembre 2019.

Histocell, S.L.

Parque Tecnológico de Bizkaia 801, 2º
48160 Derio (Bizkaia) España
T. +34 94 656 7900
reoxcare@histocell.com
www.histocell.com