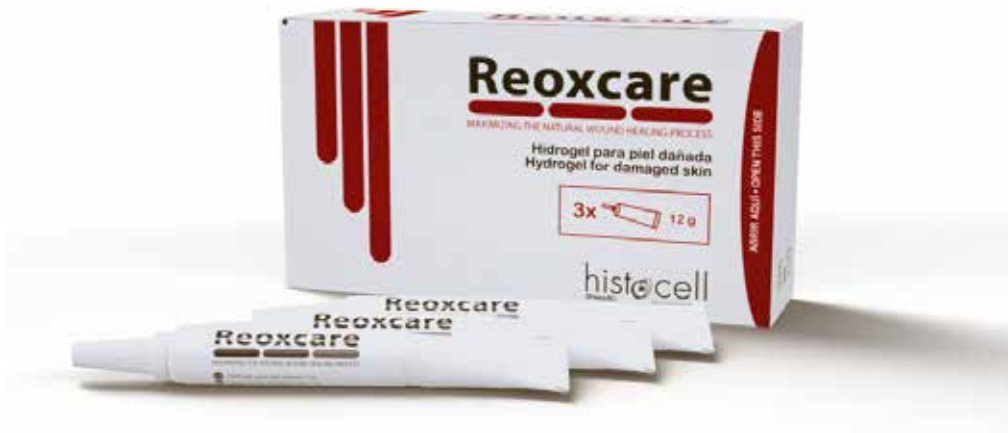

Reoxcare

MAXIMIZING THE NATURAL WOUND HEALING PROCESS

HYDROGEL FOR DAMAGED SKIN



Reoxcare Gel

What is Reoxcare Gel?

New hydrogel with ingredients of natural origin for the treatment of damaged skin and wounds of various etiologies.



Excellent clinical results

- Debridement capacity
- Protects both intact and damaged skin
- High tissue repair and healing capacity

*View scientific publications and references (www.reoxcare.com).

How is Reoxcare Gel used?

- Clean the wound carefully.
- Apply Reoxcare Gel to the area every 24/48 hours until complete recovery.
- If deemed necessary, cover with a secondary dressing.

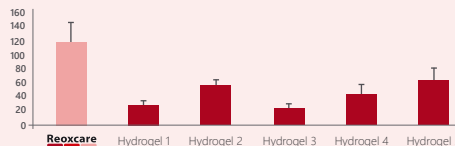
Reoxcare Gel can be used by the patient.

Reoxcare Gel is a single use product. Do not use if the container is open or damaged.
Do not use in case of known hypersensitivity to any of its components or to tomato derivatives.

What does Reoxcare Gel provide?

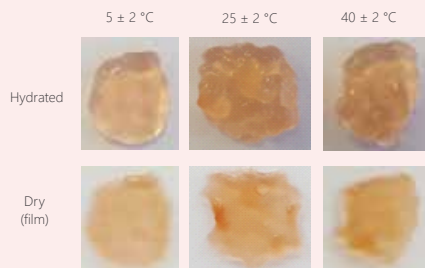
- Moisturises the skin
- Film-forming effect
- Facilitates the removal of non-viable tissue from the wound bed
- Protects the skin from continuous exposure to humidity and repairs damaged skin after aggressions

Optimal viability of skin cells



Reoxcare Gel optimally maintains fibroblast viability, contributing to skin and wound repair.

Formation of a flexible protective film



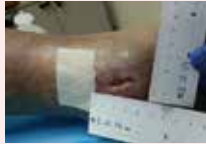Reoxcare Gel generates a resistant and flexible film, that protects the skin against the external environment.

Clinical cases

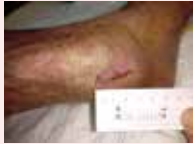

Superficial mixed vascular ulcer

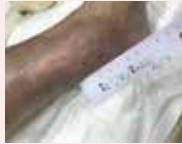73 years old. Peripheral arterial disease.
Poor tolerance to wound care materials.



Beginning



Week 3



Week 11

2 years in evolution.

Previous treatment

Hydrodetergent dressing +
metalloproteinase-reducing dressing.

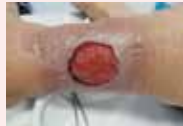Treatment with Reoxcare Gel

Cleaning + Reoxcare Gel +
hydrocolloid dressing with silver +
compressive therapy.

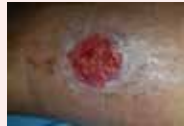

Spider bite

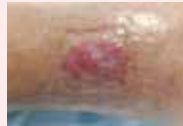77 years old. Chronic myeloid leukaemia.
Myelodysplastic syndrome, depression,
rheumatoid arthritis.



Beginning



Week 2



Week 6

2.5 months in evolution.

Previous treatment

Chlorhexidine + hydrocolloid hydrofibre
dressing with silver + protective dressing.

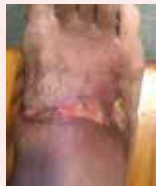Treatment with Reoxcare Gel

Sharp debridement + Reoxcare Gel +
polyurethane foam dressing.

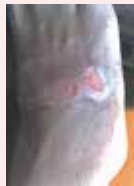

Grade II burn

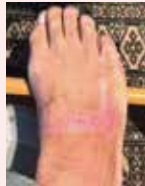54 years old. Scald injury.



Beginning



Week 2



Week 4

1 month in evolution.

Previous treatment

Argent sulfadiazine cream
and oral antibiotic.

Treatment with Reoxcare Gel

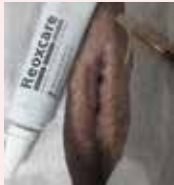Cleaning with saline solution + Reoxcare Gel
+ hydrodetergent dressing with silver or
protease regulator + protective bandage.

Clinical cases

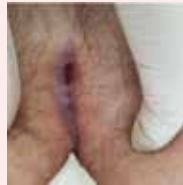

Pilonidal sinus

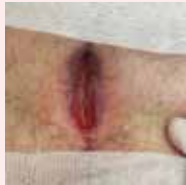22 years old. Asthma. Bronchospasm. Allergy. Reintervention of pilonidal sinus.



Beginning



Week 6



Week 7

3 months in evolution.

Previous treatment

Multiple ineffective treatments. Chlorhexidine + diakyl carbamoyl chloride dressing + support dressing.

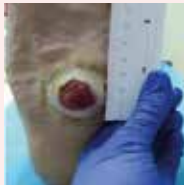Treatment with Reoxcare Gel

Sharp debridement + Reoxcare Gel + antimicrobial dressing with silver + foam dressing.

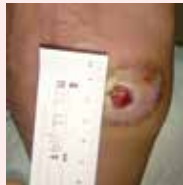

Neuropathic ulcer in Charcot's foot

51 years old. Diabetes mellitus.



Beginning



Week 3



Week 11

6 months in evolution.

Previous treatment

Daily cures with moist wound healing dressing for high serous exudate.

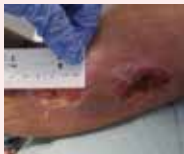Treatment with Reoxcare Gel

Cleaning + Reoxcare Gel + polyvinyl alcohol hydrofibre dressing + adhesive foam + discharge.

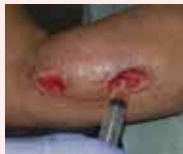

Surgical wound

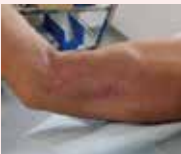53 years old. Kidney transplant. Peritoneal dialysis. Humerobasilic arteriovenous fistula surgery.



Beginning



Week 2



Week 6

1 month in evolution.

Previous treatment

Argentice sulphadiazine cream. Subsequently, debridement dressing + hydrofibre dressing + bandage.

Treatment with Reoxcare Gel

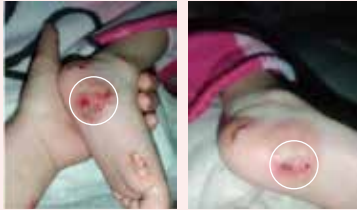Sharp debridement + Reoxcare Gel + polyurethane foam until wound closure.

Clinical cases



Traumatic injury

2 years old. Epidermolysis Bullosa Simplex



Beginning

Day 3

Previous treatment

No previous treatment.

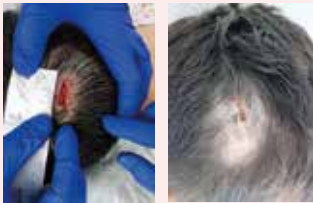Treatment with Reoxcare Gel

During the day, application of Reoxcare Gel + thin foam dressing + tubular mesh. In the evening, application of Reoxcare Gel leaving the wound to air. Application every 24 hours.



Traumatic injury

8 years old. Complex healing due to abscess.



Beginning

Week 2

1 week in evolution.

Previous treatment

Debridement and protection with gauze dressing.

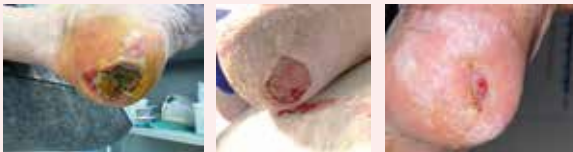Treatment with Reoxcare Gel

Reoxcare Gel + protection with gauze dressing.



Dependency-related injury

81 years old.



Beginning

Week 5

Week 10

2 months in evolution.

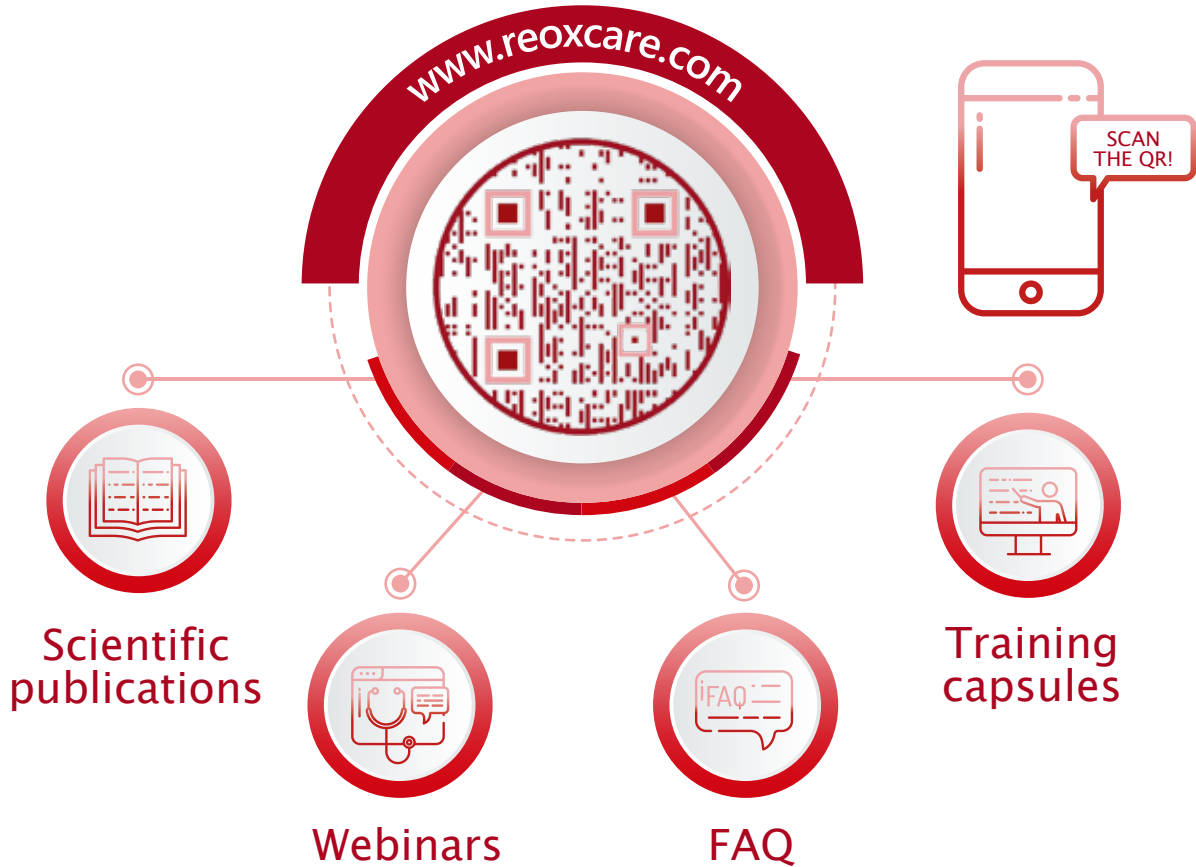
Previous treatment

Collagenase, hydrodetersive dressing with silver and 1 week of systemic antibiotic.

Treatment with Reoxcare Gel

Beginning: Reoxcare Gel with hydrodetersive dressing with silver. Changes every 48 hours. Week 5: Reoxcare Gel + moist wound healing dressing without silver.

Find out more about Reoxcare on our website!



Manufactured by:

histocell
REGENERATIVE MEDICINE

Histocell, S.L.
Parque Tecnológico 801, 2º
48160 Derio (Bizkaia) Spain
T. +34 94 656 7900 | reoxcare@histocell.com
www.histocell.com

CAT-RXG-132/V03

CE 0318